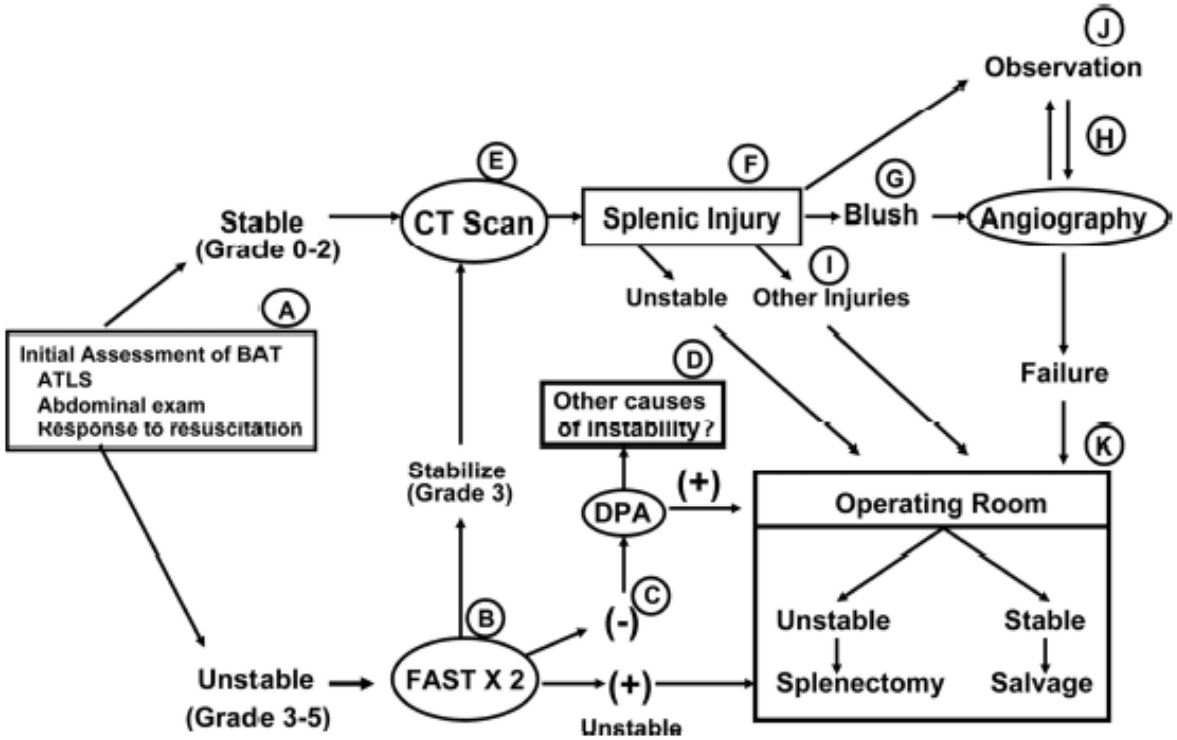

Fig. 1. *Adult blunt splenic trauma.*